Application of Kefa forest honey as antibacterial in the treatment of common carp *Cyprinus carpio* infected with bacteria *Aeromonas hydrophila*

Yuliana Salosso, Sunadji, Felix Rebhung, Komang Anggrainy

Study Program of Aquaculture, Nusa Cendana University, Kupang, Jl Adisucipto, Penfui Kupang, Indonesia. Corresponding author: Y. Salosso, yulimarasin@gmail.com

Abstract. This study aims to determine *in vitro* the right concentration of Kefa-originated forest honey and its ability to cure *Aeromonas hydrophila*-infected carp *Cyprinus carpio* through observations on the hematological change and clinical symptoms. The antibacterial activity of Kefa forest honey was tested at different concentrations (25%, 50%, and 75%) in disc method. Control treatment used antibiotic oxytetracycline. The ability of Kefa forest honey in carp treatment was carried out by infecting it with bacteria *A. hydropila* of 10^6 cells mL^{-1}. When the infection symptoms had appeared, the fish were treated with 25% honey through maceration for 3 successive days, and they were reared for 7 days. During the study, observations were done on the hematology and clinical symptoms of healthy fish, infected fish, and after treatment. Results showed that Kefa forest honey had antibacterial capability against *A. hydropila* at the dose of 25 to 75%, with inhibition zone at the concentration of 75% (16 mm) that was not significantly different from that given by antibiotics (17 mm). Kefa forest honey could also cure *A. hydropila*-infected carp by increasing the erythrocytes from 1,020,000 cells mm^{-3} in infected fish to 1,741,000 cells mm^{-3} after the treatment, increasing the haemoglobin level from 5.7 to 6.07 g 100 mL^{-1}, and reducing the leucocytes from 702,000 cells mm^{-3} in infected fish to 651,500 cells mm^{-3} after the treatment. Thus, the use of Kefa honey could cure *A. hydrophila*-infected carp indicated with the hematological changes after the treatment.

Key Words: hematology, clinical symptoms, disc method, maceration.

Introduction. Bacterial infection treatment on fish using antibiotic and other chemicals is not recommended due to their negative impacts, such as the resistance on the antibiotic or possible environmental pollution (Maisyaroh et al 2018; Maftuch et al 2018). Therefore, the use of natural materials is highly encouraged in order to reduce the negative impact of the antibiotic application (Dianti et al 2013; Susandi et al 2017; Maftuch et al 2018), including the use of natural materials in fish disease control caused by *Aeromonas hydrophila*.

A. hydrophila is one of the bacteria that often infect freshwater fish (Triyaningsih et al 2014; Orsi et al 2017), causing Motile Aeromonas Septicemia or MAS (Susandi et al 2017; Rosidah et al 2019a), and can result in up to 100% mortality (Rosidah et al 2019b). Furthermore, Lukistyowati & Kurniasi (2011) stated that *A. hydrophila* often brought about disease outbreak with death consequence up to 80-100% in a short period, about 1-2 weeks. Typical characteristics of common carp, *Cyprinus carpio* infected with MAS are alteration of skin color, haemorhage, and muscle ulcers (Laith & Najiah 2013; Susandi et al 2017).

Treatment with honey is one of the alternatives usable to overcome *A. hydrophila*-caused disease in freshwater fish culture. Honey contains numerous biological compounds with different pharmacological effects, such as antibacterial, antioxidant, anti-inflammation, and immunostimulant (Dewi et al 2017). The antioxidant activity of *Trigona incisa* honey is shown by Gunawan et al (2018) and 3 other tree honeys from New Zealand, Germany, and Algeria (Alzahrani et al 2012). The immunostimulant activity of honey is also revealed by Rosidah et al (2019a) to be able to increase the body immune system of Amur carp *Cyprinus rubrofuscus* against *A. hydrophila* infection

through feed administration at the dose of 200 mL kg^{-1}. Fuandila et al (2019) have also demonstrated the immunostimulant ability of the honey on vannamei shrimp *Litopenaeus vannamei* infected with *Vibrio parahaemolyticus*. Orsi et al (2017) have also revealed that the immunostimulant of ethanol-extracted propolis of Brazilian bee *Apis mellifera* on Nile tilapia infected with *A. hydrophila.* Honey has been proved as well to have antibacterial activity against *Staphylococcus aureus* (Dewi et al 2017; Hegazi et al 2017; Yuliati 2017), *Pseudomonas aeruginosa* (Hegazi et al 2017; Yuliati 2017), *Streptococcus mutans, Klebsiella pneumoniae*, and *Escherichia coli* (Hegazi et al 2017). Honey "Semut" (local name) from Semau Island, the Province of Nusa Tenggara Timur, and rock honey from the same province have shown antibacterial activity against *A. hydrophila* and *Vibrio alginolitycus* (Salosso 2019a, b). *In vitro* test has proved that forest honey from Kefa has antibacterial activity against *A. hydrophila* with the largest inhibition zone of 12 mm (Salosso 2019c).

To develop the benefit of Kefa forest honey as antibacterial in common carp culture, the use of the honey was studied to know *in vitro* the right concentration as antibacterial and the ability to cure the *A. hydrophila*-infected common carp through hematological and clinical symptom observations.

Material and Method

Kefa forest honey preparation and dilution. This study was conducted for 3 months, from October to December 2018. Forest honey was obtained from the forest honey collectors in Kefa, the capital of Northern Central Timor regency, the Province of Nusa Tenggara Timur. The antibacterial activity was tested against *A. hydrophila* at the concentration of 75%, 50%, and 25%. Control treatment used antibiotic oxytetracycline. The honey was diluted using sterile distilled water to obtain the desired concentrations.

Antibacterial test with disc method. The bacteria *A. hydrophila* were obtained from Fish Quarantine and Fish Quality Control Center in Kupang. The study employed Tryptone Soya Agar (TSA) media with addition of 0.5% NaCl to culture the bacteria *A. hydrophila*. On the solid TSA media was poured warm unfrozen semi-solid TSA media that has been mixed with *A. hydrophila*. After frozen, the disc paper soaked in the honey for about 30 min was located and incubated at 37°C for 24 hours, then the inhibition zone diameter was measured (Salosso 2019c).

Preparation and acclimatization of C. carpio. There were 3 types of media prepared, rearing tank, infection tank, and treatment tank. The experiment utilized 3 units of 20 L-aquaria as rearing tank, one 1 x 1 x 0.5 m fiber tank as infection tank, and a 5 L-round aquarium as treatment tank, respectively. The water used for the experiment was taken from tap water of drinking water company, the natural water that has been sterilized with 150 ppm calcium hypochlorite (Ca(ClO2) and neutralized with 75 ppm sodium thiosulfate. The fish were obtained from the Central Fish Hatchery of Noekele, Kupang regency, at the size of 8-10 cm total length. Before use, 30 fish were acclimated for 7 days in the rearing tank and they were fed with commercial pellet Eko feed-2 as much as 5% of the body weight 3 times a day, at 07.00 am, 13.00 pm, and 19.00 pm, as their nutrition need. The experiment employed standing water system that was aerated during the study and siphoned everyday to remove the fish feces. Afterwards, the fish were infected with the bacteria.

Bacterial infection on C. carpio. Twenty fish were infected with *A. hydrophila* at the density of 10^6 cells mL^{-1} by injecting 0.1 mL ind^{-1} on the base of the fish tail. The infection occurs until the fish show the infection symptoms, about 6 hours after the injection. The symptoms are indicated with declined response to the feed, abnormal swimming, red color on the injection scar, much mucus release, stomach swelling, and fallen fins, and then continued with treatment in the treatment tank.

Fish treatment. Ten infected fish were moved to the rearing tank without any treatment, while the other 10 infected fish were treated using forest honey from Kefa at

the ratio of 1 (honey): 4 (water). The treatment tank contained 200 mL honey and 800 mL water so that there were 1,000 mL of honey solution used to soak the infected fish. It was done for 12 min, then repeated for 3 successive days, and then the fish were placed in the rearing tank for 7 days. Afterwards, the fish hematology was observed.

Fish blood sampling and observations. The hematological examination was conducted before infection, after infection, and after the treatment. Blood sampling and observation were accomplished following Susandi et al (2017). The hematological observations covered only erythrocytes, haemoglobin, and leucocytes. Besides hematological observations, the clinical symptoms of the carp were recorded as well during the study. The hematological data were descriptively analyzed by comparing the hematological conditions between healthy fish, infected ones, and after the treatment.

Results and Discussion

Antibacterial test on Kefa honey. The outcome of antibacterial test on Kefa forest honey against *A. hydrophila* at different concentrations is presented in Figure 1.

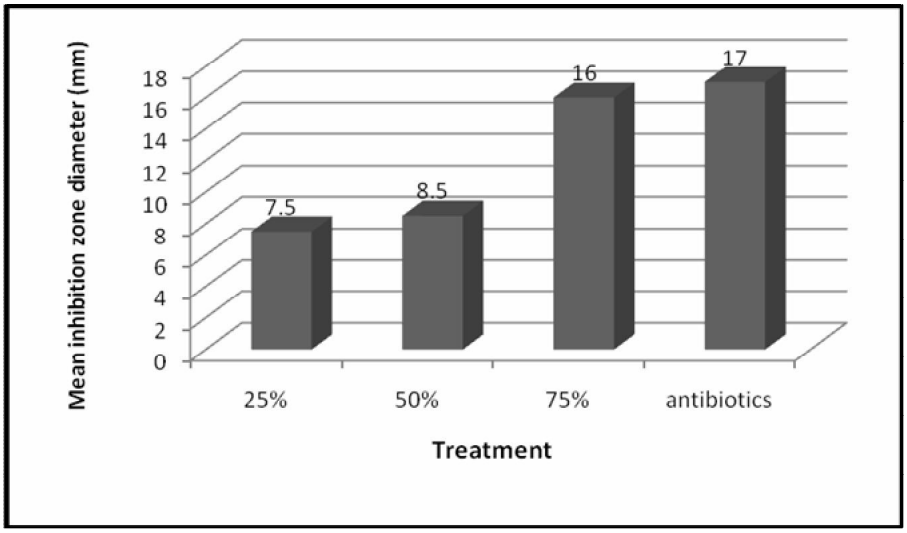

Figure 1. Mean inhibition zone diameter of Kefa forest honey against *A. hydrophila*.

The application of Kefa honey at all treatment concentrations could inhibit the growth of *A. hydrophila* with the highest inhibition zone at the concentration of 75%, 16 mm and the lowest at 25%, 7.5 mm. It means that Kefa honey is antibacterial against *A. hydrophila*. The inhibition zone reached at the concentration of 75% is also not far different from that given by the antibiotics oxytetracycline.

The ability of antibacterial activity of Kefa forest honey could occur through several mechanisms. First, it has high glucose content, 72.6% (Salosso 2019c), that will inhibit the bacteria to live and develop. Second, the presence of antibacterial organic compounds (Libonatti et al 2014), such as saponin and alkaloid (Salosso 2019c). These organic compounds make the honey have antibacterial activity (Libonatti et al 2014). Also, the presence of radical compounds as hydrogen peroxide (H_2O_2) can kill pathogenic organisms (Libonatti et al 2014; Nadhilla 2014; Johnston et al 2018). Third, it has low pH, 4.06 (Salosso 2019c); high acidity will reduce the growth and the survival of the bacteria and kill them (Libonatti et al 2014; Nadhilla 2014; Johnston et al 2018).

Hematological change in A. hydropilla-infected C. carpio with Kefa honey

Erythrocytes. Red blood cells (erythrocytes) containing hemoglobin are complex proteins that possess the ability to bind oxygen (Dewantoro 2019). Changes in number of erythrocytes of common carp in the present study are given in Figure 2.

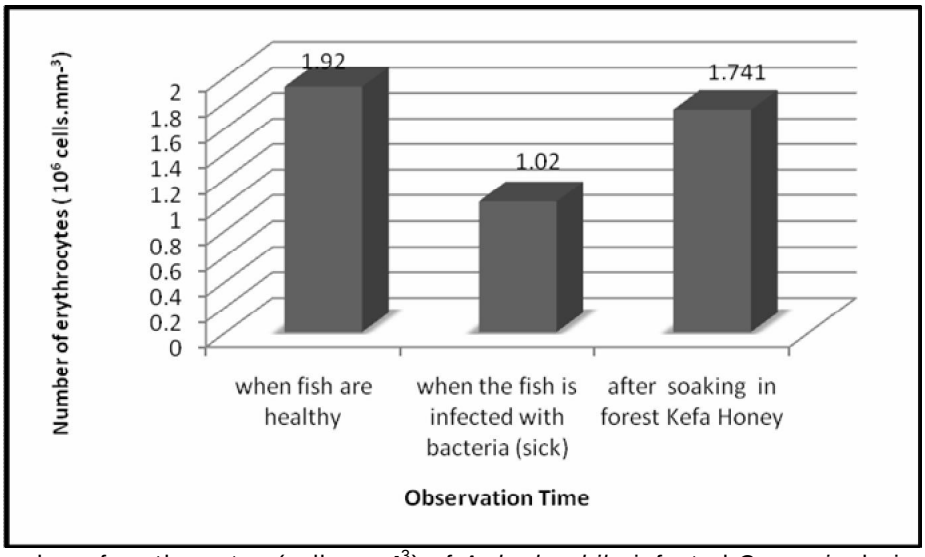

Figure 2. Number of erythrocytes (cells mm^{-3}) of *A. hydrophila*-infected *C. carpio* during the study.

Figure 2 demonstrates that healthy common carp has the erythrocytes up to 1,920,000 cells mm^{-3} while the sick common carp experiences erythrocyte reduction down to 1,020,000 cells mm^{-3}. Nevertheless, the number of erythrocytes rises again to 1,741,000 cells mm^{-3} after soaking the fish in Kefa honey solution for 3 successive days. It indicates that soaking the carp in Kefa honey could give the recovery effect since the number of erythrocytes rise close to normal level. The same situation occurred in common carp that recovered from *A. hydrophila* infection after soaked in *Coleus scutellarioides* leaves mixed with honey, in which the erythrocytes rise from 1,030,000 cells mm^{-3} (sick fish) to 1,450,000 cells mm^{-3} (after soaking), approaching to that of healthy fish, 1,510,000 cells mm^{-3} (Salosso 2018).

Number of erythrocytes of healthy common carp in the present study (1,920,000 cells mm^{-3}) was lower than that found by Riantono et al (2016), 2,360,000 cells mm^{-3} and Dianti et al (2013), 2,980,000 cells mm^{-3}. It indicates that the same species (which is common carp) could have varied number of erythrocytes. This finding also reconfirms Ejraei et al's (2015) study that number of erythrocytes is dependent upon fish species, age, nutrition, and environmental conditions.

In *A. hydrophila*-infected common carp (sick condition), the fish experience declined number of erythrocytes. It could result from exotoxic enzymes produced by *A. hydrophila* as virulent, such as protease and hemolysin. According to Triyaningsih et al (2014), *A. hydrophila* can yield protease enzyme and hemolysin as virulent in fish. Protease is an enzyme that is able to fight against the host body defense for disease development and take the nutrient supply, while hemolysin dissolved in the blood can lyse the erythrocytes and break the hemoglobin so that much blood goes out from the infected body. It causes haemorhage in *A. hydrophila* -infected fish.

The erythrocytes of common carp rise again after soaking in honey solution, reflecting the honey capability of inhibiting the growth of *A. hydrophila* that infects the fish. The antibacterial activity of Kefa forest honey has been *in vitro* proved through the presence of inhibition zone and to cure *A. hydrophila*-infected fish through hematological change approaching to normal. The recovery of *A. hydrophila*-infected common carp occurs through antibacterial mechanism of Kefa forest honey from its high sugar content, acidic pH, and antibacterial compound (Hegazi et al 2017; Yuliati 2017; Salosso 2019c).

Leucocytes. The change pattern of white blood cell (leucocytes) in common carp is different from that in the erythrocytes. The change of leucocytes amount is shown in Figure 3.

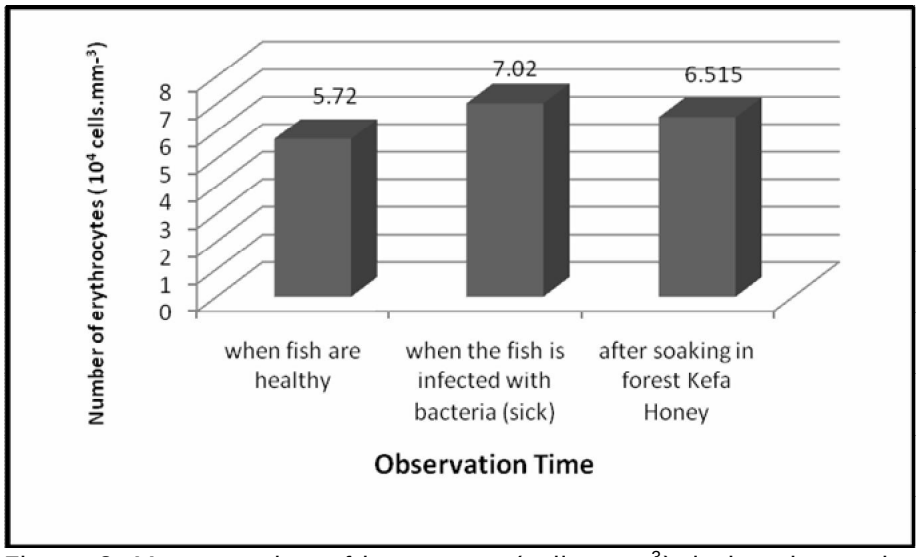

Figure 3. Mean number of leucocytes (cells mm^{-3}) during the study.

The leucocytes of healthy common carp are only 572,000 cells mm^{-3} and could reach 702,000 cells mm^{-3} in sick common carp. Increased leucocytes in the infected fish are one of the body reactions in fighting the bacterial infection. It is in agreement with Dwinanti et al (2014) that the increased number of leucocytes indicates that the fish in infected conditions will release more leucocytes as immunity response.

Increased number of leucocytes in the infected fish occurs also in *A. hydrophila*-infected catfish *Clarias gariepinus* from 70,020 to 103,300 cells mm^{-3} (Rosidah et al 2019a). The number of leucocytes in *A. hydrophila*-infected common carp rises also from 27,300 to 34,700 cells mm^{-3} (Dianti et al 2013), and from 75,200 to 82,733 cells mm^{-3} in infected *Carassius auratus* (Rosidah et al 2019b). Nile tilapia *Oreochromis niloticus* infected with *Flavobacterium columnare* has increased number of leucocytes from 19,500 to 29,500 cells mm^{-3} (Sebastiao et al 2011).

Leucocytes function in defense system to the pathogenic infection. Therefore, as the fish are infected by bacteria, their number of leucocytes rises (Fauzan et al 2017). Treatment with honey will help the fish body defense system fight the bacterial infection. Rosidah et al (2019b) stated that various compounds in the honey are supporting to increase the fish immune system to work as immunostimulant.

Honey has ability as a strong antioxidant and to inhibit the free radical formation, so that it can protect the cell component from hazardous substances (Alzahrani et al 2012). According to Puertollano et al (2011), antioxidant compounds possess close relationship with body immune system since it helps protect the immune cells from damages as a result of free radicals.

Vitamin C is one of the compounds acting as antioxidant. One of the substances contained in honey, according to Bogdanov et al (2008), is ascorbic acid. Vitamin C content in honey raises the body defense system by stimulating the interferon (Rosidah et al 2019b). Similar opinion is also given by Van Gorkom et al (2018) that vitamin C increases the interferon and the immune cell activity, lymphocytes, and macrophages. Carr & Maggini (2017) found that vitamin C gave beneficial effects on derivative cellular function and adaptive immune system, stimulated neutrophils migration to the infected site in order to develop the phagocytosis. The intake of vitamin C is reported to be able to make the body be more resistant to infections by possibly producing interferon and leucocytes besides maintaining the inflammatory process (Van Gorkom et al 2018). The antioxidant and immunostimulant mechanisms of the honey-contained compounds have helped the healing process of *A. hydrophila*-infected common carp so that their blood composition could return to normal condition.

Hemoglobin. Changes in hemoblogin level of common carp during the study are presented in Figure 4.

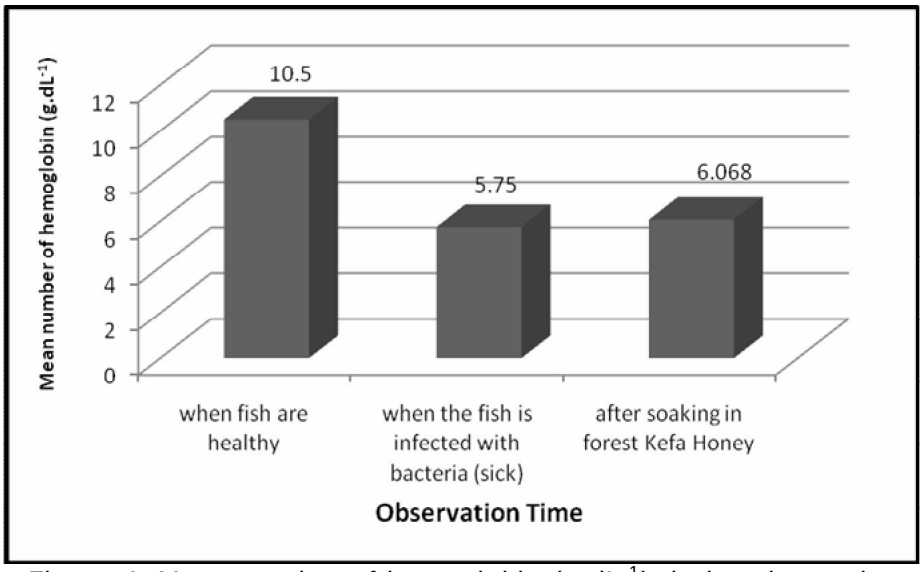

Figure 4. Mean number of hemoglobin (g dL^{-1}) during the study.

The highest mean hemoglobin was recorded in healthy fish as much as 10.5 g dL^{-1}, while the lowest in the infected fish was 5.7 g dL^{-1}. The hemoglobin level drops in the sick/infected fish, but it rises again to 6.07 g dL^{-1} after treated with Kefa honey. Change in hemoglobin level is similar to that in the erythrocytes (Figure 2). Fish hemoglobin level is highly correlated with the number of erythrocytes because hemoglobin occurs in the erythrocytes.

Thus, declined number of erythrocytes in the infected fish will be followed with decline in hemoglobin level (Triyaningsih et al 2014). The hemoglobin in the erythrocyte has the role to bind oxygen so that it could well determine the capability of the fish metabolism (Dewantoro 2019). Low hemoglobin level makes the blood oxygen amount be low (Palmi et al 2019), followed by declined metabolism rate and low energy produced. As a result, the fish will lose their appetite as one of the infected fish behavior.

Increase in hemoglobin level of the fish treated with honey reflects that honey could cure the fish infected with *A. hydrophila*. The ability of honey to cure *A. hydrophila*-infected common carp could occur through antibacterial, antioxidant, and imunostimulant mechanisms of the honey as reported by Dewi et al (2017) that honey has antibacterial, antioxindant, anti-inflammatory effects and increase the immune system.

Clinical symptoms of C. carpio during the study. The fish clinical synptoms during the study are presented in Figure 5.

Figure 5a shows the clinical symptoms of fish in normal conditions, i.e. the fish have bright color and the scale is sunny, intact, and there is no reddish skin. In *A. hydrophila*-infected fish, there are infection symptoms, such as wounds on the injected back part, red color appearance on the skin, removed scales (Figure 5b). Similar clinical symptoms are also found in several *A. hydrophila*-infected freshwater fish, such as catfish *C. gariepinus* (Triyaningsih et al 2014; Rosidah et al 2019a), *C. carpio* (Dianti et al 2013), gourame (*Osphronemus gouramy*) (Susandi et al 2017), and tilapia (*Oreochromis niloticus*) (Maisyaroh et al 2018). The appearance of clinical symptoms on the wound and hemmorhage on the fish body surface could result from toxin produced by *A. hydrophila,* one of which is hemolysin. According to Pratama et al (2017), the presence of red color on the fish body surface is also caused by the activity of hemolysin released by *A. hydrophila* to break down the erythrocytes, the cells leave the blood and produce reddish color on the skin surface.

After the fish have shown bacterial infection symptoms, they are immediately treated using Kefa honey through soaking method. After 3 successive days of treatment, the fish start showing good response when fed, and the wound is slowly cured, the wound disappears, and the fish color will turn bright (Figure 5c).



Figure 5. *C. carpio* appearance during the study: healthy fish, infected fish, after treatment fish.

Conclusions. The forest honey from Kefa was antibacterial against *A. hydrophila* from the dose of 25 to 75%, and the inhibition zone given at the concentration of 75% (16 mm) was not quite different from that given by the antibiotics (17 mm). It could also cure *A. hydropila*-infected *C. carpio* by increasing the erythrocytes from 1,020,000 cells mm^{-3} (infected fish) to 1,741,000 cells mm^{-3} (after treatment), increasing the hemoglobin from 5.7 g 100^{-1} mL (infected fish) to 6.07 g 100^{-1} mL (after treatment), and reducing the leucocyte amount from 702,000 cells mm^{-3} (infected fish) to 651,500 cells mm^{-3} (after treatment).

References

Alzahrani H. A., Boukraa L., Bellik Y., Abdellah F., Bakhotmah B. A., Kolayli S., Sahin H., 2012 Evaluation of the antioxidant activity of three varieties of honey from different botanical and geographical origins. Global Journal of Health Science 4(6):191-196.

Bogdanov S., Jurendic T., Sieber R., Gallmann P., 2008 Honey for nutrition and health: a review. American Journal of The College of Nutrition 27:677-689.

Carr A. C., Maggini S., 2017 Vitamin C and immune function. Nutrients 9:1211.

Dewi M. A., Kartasasmita R. E., Wibowo M. S., 2017 [Antibacterial activity tests on several types of Indonesian honey against Staphylococcus aureus and Escherichia coli]. Kartika: Jurnal Ilmu Farmasi 5(1):27-30. [in Indonesian]

Dewantoro E., 2019 [Hematological performance of tinfoilbarb (*Barbonymus schwanenfeldii*) reared on various water aeration levels]. Jurnal Ruaya 7(2):26-33. [in Indonesian]

Dianti L., Prayitno S. B., Ariyati R. W., 2013 [Non specific resistance of carp (*Cyprinus carpio*) soaked in the extract of *Acanthus ilicifolius* leaf against *Aeromonas hydrophila* bacterial infection]. Journal of Aquaculture Management and Technology 2(4):63-71. [in Indonesian]

Dwinanti S. H., Sukenda, Yuhana M., Lusiastuti A. M., 2014 [Toxicity and immunogenicity of of non-haemolytic type *Streptococcus agalactiae* of extracellular products in Nile tilapia (*Oreochromis niloticus*)]. Jurnal Akuakultur Rawa Indonesia 2(1):105-116. [in Indonesian]

Ejraei F., Ghiasi M., Khara H., 2015 Evaluation of hematological and plasma indices in grass carp, *Ctenopharyngodon idella*, with reference to age, sex, and hormonal treatment. Archives of Polish Fisheries 23:163-170.

Fauzan M., Rosmaidar, Sugito, Zuhrawati, Muttaqien, Azhar, 2017 [The influence of the level of lead (Pb) exposure on the blood profiles of tilapia fish (*Oreochromis niloticus*)]. Jimvet 1(4):702-708. [in Indonesian]

Fuandila N., Widanarni, Yuhana M., 2019 Growth performance and immune response of prebiotic honey fed Pacific white shrimp *Litopenaeus vannamei* to *Vibrio parahaemolyticus* infection. Journal of Applied Aquaculture DOI: 10.1080/10454438.2019.1615593

Gunawan R., Erwin, Syafrizal, 2018 [Phytochemical test and antioxidant activity determination of stingless bee *Trigona incisa* honey]. Jurnal Atomik 3(1):18-21. [in Indonesian]

Hegazi G. A., Al Guthami F. M., Al Gethami A. F. M., Abd Allah F. M., Saleh A. A., Fouad E. A., 2017 Potential antibacterial activity of some Saudi Arabia honey. Veterinary World 10(2):233-237.

Johnston M., McBride M., Dahiya D., Owusu-Apenten E., Nigam P. S., 2018 Antibacterial activity of Manuka honey and its components: an overview. AIMS Microbiology 4(4): 655-664.

Laith A. R., Najiah M., 2013 *Aeromonas hydrophila*: antimicrobial susceptibility and histopathology of isolates from diseased catfish, *Clarias gariepinus* (Burchell). Journal of Aquaculture Research and Development 5(2):215.

Libonatti C., Soledad V., Marina B., 2014 Antibacterial activity of honey: a review of honey around the world. Journal of Microbiology and Antimicrobials 6(3): 51-56.

Lukistyowati I., Kurniasih, 2011 [The survivorship of carp *Cyprinus carpio* fed with *Allium sativum* extract-containing feed against *Aeromonas hydrophila]*. Jurnal Perikanan dan Kelautan 16(1):144-160. [in Indonesian]

Maftuch, Setyawan F. H., Suprastyani H., 2018 [Inhibitability test of *Chaetoceros calcitrans* extract against bacteria *Aeromonas salmonicida*]. Journal of Fisheries and Marine Research 2(1):39-46. [in Indonesian]

Maisyaroh L. A., Susilowati T., Haditomo A. H. C., Basuki F., Yuniarti T., 2018 [The use of mangosteen (*Garcinia mangostana*) skin as antibacterial to treat infection of *Aeromonas hydrophila* in Nile tilapia (*Oreochromis niloticus*)]. Jurnal Sains Akuakultur Tropis 2(2):36-43. [in Indonesian]

Nadhilla N. F., 2014 [The activity of antibacterial agent of honey against *Staphylococcus aureus*]. Jurnal Majority 3(7):94-101. [in Indonesian]

Orsi R. O., Dos Santos V. G., Pezzato L. E., De Carvalho P. L. P. F., Teoxeira C. P., Freitas J. M. A., Podovani C. R., Sartori M. M. P., Barros M. M., 2017 Activity of Brazilian propolis against *Aeromonas hydrophila* and its effect on Nile tilapia growth, hematological and non-specific immune response under bacterial infection. Anais da Academia Brasileira de Ciencias 89(3):1785-1799.

Pratama R. C., Rosidah, Sriati, Rustikawati I., 2017 [Effectivity of rambutan seed extract to treat carp seed infected with *Aeromonas hydrophila*]. Jurnal Perikanan dan Kelautan 8(1):130-138. [in Indonesian]

Palmi R. S., Yudha I. G., Wardiyanto, 2019 [The effects of amethyst *Datura metel* (Linn, 1753) leaves extract as an anesthetic agent on haematological condition of tilapia *Oreochromis niloticus* (Linn., 1758) fry]. e-Jurnal Rekayasa dan Teknologi Budidaya Perairan 8(1):897-908. [in Indonesian]

Puertollano M. A., Puertallano E., Cienfuegos G. A., Pablo M. A., 2011 Dietary antioxidants: immunity and host defense. Current Topics in Medical Chemistry 11:1752-1766.

Riantono F., Kismiyati, Sulmartiwi L., 2016 [Hematological changes in comet goldfish (*Carassius auratus auratus*) as a result of infestation *Argulus japonicus* males and *Argulus japonicus* females]. Journal of Aquaculture and Fish Health 5(2):28-35. [in Indonesian]

Rosidah, Buwono I. D., Lili W., Suryadi I. B., Triandika A. R., 2019a [The resistance of sangkuriang catfish (*Clarias gariepinus* Burchell 1822) against *Aeromonas hydrophila* bacteria given moringa leaf extracts (*Moringa oleifera* L.)]. Jurnal Iktiologi Indonesia 19(1):97-113. [in Indonesian]

Rosidah, Sriati, Subhan U., Mulyani Y., Dermawan R., 2019b [The effectiveness of honey supplementation in feed for improving goldfish fingerling *Carassius auratus* immune system against *Aeromonas hydrophila* bacteria attack]. Jurnal Akuakultur Indonesia 18(1):89-100. [in Indonesian]

Salosso Y., 2018 [The use of mayleaf mixed with honey in the treatment of carp (*Cyprinus Carpio*) infected with *Aeromonas hydrophila*]. Prosiding Simposium Nasional Kelautan dan Perikanan V Universitas Hasanuddin, Makassar, 5 Mei 2018, ISBN 978-602-71759-5-2. [in Indonesian]

Salosso Y., 2019a [Antibacterial test of ants honey from Semau Island against *Aeromonas hydrophila* and *Vibrio alginolitycus* bacteria]. Jurnal Sains Dan Inovasi Perikanan 3(2):68-72. [in Indonesian]

Salosso Y. 2019b Chemical composition and antibacterial activity of honey collected from East Nusa Tenggara, Indonesia on pathogenic bacteria in aquaculture. IOP Conference Series: Earth and Environmental Science 370:012030.

Salosso Y., 2019c The potential of forest honey (*Apis* spp.) from Timor Island as antibacterial against pathogenic bacteria in fish culture. Indonesian Aquaculture Journal 14(2):63-68.

Sebastiao F. A., Nomura D., Sakabe R., Pilarski F., 2011 Hematology and productive performance of Nile tilapia (*Oreochromis niloticus*) naturally infected with *Flavobacterium columnare*. Brazilian Journal of Microbiology 42(1):282-289.

Susandi F., Mulyana, Rosmawati, 2017 [Increased immunity of giant gouramy (*Osphronemus gouramy* Lac.) fry against *Aeromonas hydrophila* bacteria used roselle (*Hibiscus sabdariffa* L.)]. Jurnal Mina Sains 3(2):1-12. [in Indonesian]

Triyaningsih, Sarjito, Prayinto S. B., 2014 Patogenisitas *Aeromonas hydrophila* yang diisolasi dari lele dumbo *Clarias gariepinus* yang berasal dari Boyolali. Journal of Aquaculture Management and Technology 3(2):11-17. [in Indonesian]

Van Gorkom G. N. Y., Wolterink R. G. J. K., Van Eissen C. H. M. J., Wietien L., Germeraad W. T. D., Bos G. M. J., 2018 Influences of vitamin C on lymphocytes: an overview. Antioxidants 7(3):41.

Yuliati, 2017 [Effectivity test of honey solution as antibacterial against the growth of *Staphylococcus aureus* and *Pseudomonas aeruginosa* with disk diffusion method]. Jurnal Profesi Medika 11(1):7-15. [in Indonesian]

Received: 23 March 2020. Accepted: 17 April 2020. Published online: 24 April 2020.
Authors:
Yuliana Salosso, Study Program of Aquaculture, Nusa Cendana University, Kupang, Jl Adisucipto, Penfui Kupang, Indonesia, e-mail: yulimarasin@gmail.com
Sunadji, Study Program of Aquaculture, Nusa Cendana University, Kupang, Jl Adisucipto, Penfui Kupang, Indonesia, e-mail: sunadji.undana60@gmail.com
Felix Rebhung, Study Program of Aquaculture, Nusa Cendana University, Kupang, Jl Adisucipto, Penfui Kupang, Indonesia, e-mail: felixrebhung.therapymusik@gmail.com
Komang Anggrain, Study Program of Aquaculture, Nusa Cendana University, Kupang, Jl Adisucipto, Penfui Kupang, Indonesia, e-mail: Liemey10@gmail.com

How to cite this article:
Salosso Y., Sunadji, Rebhung F., Anggrainy K., 2020 Application of Kefa forest honey as antibacterial in the treatment of common carp *Cyprinus carpio* infected with bacteria *Aeromonas hydropila*. AACL Bioflux 13(2):984-992.