

Histopathological alterations in the gill of zebrafish (*Danio rerio*) exposed to Cr and Ba doped TiO₂ nanoparticles

¹Raouf Rahmani, ²Borhan Mansouri, ³Nammam A. Azadi, ⁴Behrouz Davari, ⁵Seyed A. Johari, ¹Afshin Maleki, ¹Mohammad A. Pordel

¹ Environmental Health Research Center, Kurdistan University of Medical Sciences, Sanandaj, Iran; ² Student Research Committee, Kurdistan University of Medical Sciences, Sanandaj, Iran; ³ Biostatistics Department, School of Public Health, Iran University of Medical Sciences, Tehran, Iran; ⁴ Department of Entomology, School of Medicine, Hamadan University of Medical Sciences, Hamadan, Iran; ⁵ Department of Fisheries, Faculty of Natural Resources, University of Kurdistan, Kurdistan, Sanandaj, Iran.
Corresponding author: B. Mansouri, borhanmansouri@yahoo.com

Abstract. In order to improve the photocatalytic efficiency of titanium dioxide, doping it with metals has been suggested; however, toxicity studies of metal-doped nanoparticles on aquatic organisms are not completely known. Therefore, the purpose of this study was to evaluate the short term effect of exposure to Cr and Ba doped TiO₂ nanoparticles (NPs) using gill histopathology of zebrafish (*Danio rerio*) under laboratory condition. In this study, four concentration levels, 1, 10, 32, and 100 mg L⁻¹ of each Cr and Ba doped TiO₂ NPs as well as a control group were used. After 4 days of exposure, from each experimental group, three samples of fish gill prepared to study the classic histology (haematoxylin – eosin). The results of this study showed that the Cr and Ba doped TiO₂ NPs can cause gill alterations including aneurism, dilated and clubbed tips, hyperplasia, oedema, curvature, fusion of lamellae, increase of mucous secretion, and proliferation in the erythrocytes of cartilaginous core. The extent of tissue damages increased by concentration levels of NPs; however, the severity of injuries caused by Cr was more notable than that of observed by Ba.

Key Words: metal-doped, chromium, titanium dioxide, hyperplasia, fusion of lamellae.

Introduction. Nanotechnology is known as the engineering of a system from its molecular scale to fabricate nanomaterials. It is also refer to manipulation of atoms for manufacturing macro-materials. With a broad application across various science fields, it also used in household textile manufacturing, electronics, medical products, and technologies to extract biological contaminants (Ates et al 2013). In 2010, the annual consumption of nanomaterials was estimated 118,768 metric tons with an economical value over \$800 million (BCC Research 2010). Nanotechnology consumer product inventory showed increasing use of nanoparticles incorporated into consumer products across the globe; while it comprised only 54 products in 2005, this figure jumped to 1,628 products by 2013 (Maynard & Michelson 2006; Woodrow Wilson Database 2014). Moreover, European commission (2015) estimates the global value of nanotechnology applicants to grow from 200 bn € in 2009 to 2 trn € by 2015. Nanoparticles can be toxic and they may release hazardous components into our aquatic ecosystem through industrial discharges, sewages, mining wastes, agricultural wastewater effluents, and accidental spillages (Rana & Kalaichelvan 2013; Jiss et al 2014). Thus, a raising concern about the potential threads of using nanoparticles for environment has recently emerged among scientists.

Barium (Ba) is a metal that naturally exist in environment. The concentration of Ba in sea and fresh water is approximated to be 13 and 2.6mg/L respectively (Pais & Jones 1998). Paper and textile industries, pesticides, paints, fuel additives, steel/metal alloys, and waste disposal sites are main users of barium compounds (Purdey 2004).

Barium can react with other materials to produce toxic compounds. Its salt can be extremely toxic to humans, animals, and plants (Jacobs et al 2002; Llugany et al 2000; Kuperman et al 2006). Barium exposure is known for multiple biological defects by affecting the life span, development, reproduction, and locomotion behaviors of nematode *Caenorhabditis elegans* (Wang & Wang 2008).

Chromium (Cr) is another nonessential metal for humans, which may cause health problems. Excessive uptake of Cr can result in various health issues as well (Jaishankar et al 2014). Chromium can enter air, soil, and water through human activities such as effluent discharged from tannery, paint, and textile manufacturing, electro painting, welding, grinding, photographic and pharmaceutical industries (Rajaei et al 2012; Ahmed et al 2013; Fernando et al 2015). In an aquatic organism such as fish, chromium has the tendency to accumulate in tissues through gill surfaces and gut tract wall (Chevreuil et al 1995) with various toxicity effects such as acute toxicity and genotoxicity (Ahmed et al 2013), oxidative stress and DNA Damage (Kumar et al 2013), and hematological and histopathological changes (Wepener et al 1992; Mishra & Mohanty 2009). Several reports are available on histopathological responses of fish gills to the toxic effects of chromium (Nath et al 1997; Parvathi et al 2011; Fernando et al 2015). Mishra & Mohanty (2008) claimed histopathological alterations such as epithelial hyperplasia, lamellar fusion, oedema, epithelial lifting, and epithelial necrosis in the gill of *Channa punctatus* following exposure to Cr. Begum et al (2006) found necrosis, hypertrophy and hyperplasia in secondary lamellae of *Gambusia affinis* gills as after contacting with Cr.

Titanium dioxide (TiO₂) nanoparticles are used widely in cosmetic and skin care products. It is also used in industry (color, glossy poster paper, and catalytic activity), and biomedical products such as orthodontics, dental implants, and drug systems. TiO₂ NPs are photocatalytic and this property of TiO₂ is particularly useful for environmental degradation studies, i.e. PCBs, pesticides, and other complex organic contaminant studies in water (Muneer et al 2002; Lhomme et al 2005). In order to improve the photocatalytic efficiency of titanium dioxide, doping it with transition metals such as Cr, Ni, and Ba has been suggested (Zhang 2011; Tian et al 2012; Wang et al 2015a). However, the toxicity of such transition on aquatic organisms is not completely known. Some studies have reported the toxicity of TiO₂ NPs when combined with other metals; for example, Wang et al (2011) found that the combination of As with TiO₂ NPs can escalate toxicity. Fan et al (2012) found development of oxidative stress and physiological damages in *Daphnia magna* after doping Cu with TiO₂ NPs.

The appropriateness of fish as a biological indicator to assess the acute and chronic toxicity of non-doping TiO₂ nanoparticles has been suggested by several authors (Federici et al 2007; Hao et al 2009; Ates et al 2013); Some of these studies suggest histopathological alterations in the fish liver, gill, and intestine (Federici et al 2007; Hao et al 2009). In other hand, toxicity studies of metal-doped nanoparticles using fish are much rarer. In a comparative study, Yeo & Park (2012) showed mitochondria damages and embryonic development of zebrafish (*Danio rerio*) for pure TiO₂ exposed group and a group treated with Cu-doped TiO₂. Yeo & Kang (2010) studied the biological toxicity of pure TiO₂ and Zn-doped TiO₂ NPs on freshwater *Hydra magnipapillata* and observed no cytotoxic effect such as apoptosis and necrosis. To our knowledge, the primary focus of existing studies is the biological effects of metal-doped TiO₂ nanoparticles whereas the histopathological effects of these nano-scale particles have been less discovered. Thus, as an attempt to provide the toxicity evidence, our main goal was to investigate the effects of Cr and Ba-doped TiO₂NPs on gill histopathology of *D. rerio* under controlled experimental condition.

Material and Method. We acquired titanium dioxide nanoparticles (TiO₂ NPs) from Nano Sani Co. (Mashhad, Iran). Reagent grade Cr (as CrO) and Ba (as BaO), triethylamine and HCl were purchased from Merck, Germany. Nanoparticle synthesis initiated by using 2.0 moles of TiO₂. Under a mild hydrothermal condition (T = 100°C, P = autogenous, t = 8 h), the surface modified Cr and Ba-doped TiO₂ were added at 1% Wt rate. As mineralizer, 1.0 mole of triethylamine was applied to the mixture. After adding 1.0 mL of triethylamine and stirring vigorously for a few minutes, the final compound transferred to

the Teflon liner ($V_{\text{fill}} = 10 \text{ mL}$) to be placed later inside a general purpose autoclave. The assembled autoclave was kept in an oven with 100°C for 8 h and then cooled down to the room temperature. The product in the Teflon liner shifted to a clean beaker, washed with double distilled water several times, and allowed to settle down. The surplus solution was removed using a syringe and the rest dried naturally at room temperature. The dried particles were subjected to systematic characterization and photocatalytic studies. Figure 1 shows the scanning electron microscopy (SEM) image of Cr and Ba doped TiO_2 NPs.

D. rerio samples used in this study were obtained from a local aquaculture shop in Sanandaj city. The length of fish samples (male) varied from 2 to 4 cm with their weights varying from 2 to 4 g. The subjects were acclimatized under laboratory conditions for one week before running experimentation. Fish was not feed 2 4h before or during the experiment. The experiment composed of nine experimental groups; a control group and eight predefined concentrations of Cr/Ba, doped TiO_2 ($1.0, 10, 32, \text{ and } 100 \text{ mg L}^{-1}$). Ten fish randomly assigned to each group; first group was the control and second to fifth groups were Cr doped TiO_2 NPs; sixth to ninth groups were Ba doped TiO_2 NPs. Experimentation period took four days. Of each group, three fish selected randomly and transferred to an aquarium holding 12 L water with three replicates. To preserve the level of metal doped TiO_2 NPs, the water of aquariums was renewed every 48 hours. The specification of water was: pH 7.2 ± 0.4 , temperature $28.0 \pm 2^{\circ}\text{C}$, and dissolved oxygen content (DO) $6.3 \pm 0.3 \text{ mg/L}$. The aquariums were inspected after 24, 48, 72 and 96 hours for casualties. No casualty was observed during the experimental period either in control or treatment groups.




Figure 1. SEM of Cr (left) and Ba (right) doped TiO_2 NPs (source: University of Kurdistan).

For histological study purpose, the gill tissue was removed by surgery and placed into 10% buffered formalin solution immediately. After one hour, sample was dehydrated and then inserted into paraffin wax. Using a microtome, a $5 \mu\text{m}$ slice was obtained from resulting sample and stained with haematoxylin and eosin (Mansouri et al 2015). The diameter and length of secondary gill lamellas as well as diameter of gill filaments were measured using Axio Vision (Release 4.8.2). Axio Vision, a modular image-processing and analysis system, is microscope software for different applications in the field of biological and medical routine research. Moreover, Axio Vision allows visualizing and presenting images in several dimensions.

Since the goal of this study was to investigate whether exposure to pre-defined levels of Ba/Cr doped TiO_2 NPs affect the gills structure of *D. rerio* (that is, the length of secondary lamella [L1], diameter of secondary lamellae [D2], and primary diameter of lamellae [D1]) a two-way ANOVA with two between subject factors was used. Data were log transformed to obtain normal distributions that satisfied the homogeneity of variance

as well as normality assumption required by ANOVA. To explore the mean differences of each parameter at different concentration levels, the post-hoc Tukey's HSD test was performed.

Results and Discussion. The results of performing three independent two-way ANOVAs with two between subject factors and their interactions are given in Table 1. The effect of concentration was highly significant on the length of secondary lamella (L1), primary diameter of lamellae (D1), and diameter of secondary lamellae (D2), ($F_{L1} [4, 180] = 12.56$; $p < 0.001$, $F_{D1} [4, 180] = 14.31$; $p < 0.001$, and $F_{D2} [4, 180] = 17.70$; $p < 0.001$). In order to inspect the mean differences between groups for each parameter in greater details, the 95% pairwise confidence intervals (CIs) of gill parameters are presented by Figure 2. In this Figure, for L1, there are four CIs crossing the dotted vertical line representing no difference between means. Majority of CIs are in the right side of zero line (vertical line) indicating significant decreasing in the length of gill. Of comparison between CIs for L1, we can conclude that increasing NP concentration up to 10 mg L^{-1} makes no significant changes in the length of secondary lamella. At 32 and 100 mg L^{-1} concentration levels the length began to decay so that at 100 mg L^{-1} highest reduction in L1 happened.

Table 1

The results of two-way ANOVA analysis for gill parameters*

		<i>Sum of squared</i>	<i>DF</i>	<i>F-ratio</i>	<i>P-value</i>
Primary length (L1)	Doped metal	109	1	0.561	0.45
	Concentration	9779	4	12.57	<0.001
	Interaction	3489	4	4.48	0.002
	Residuals	35020	180		
		<i>Sum of squared</i>	<i>DF</i>	<i>F-ratio</i>	<i>P-value</i>
Primary diameter (D1)	Doped metal	363	1	5.32	0.02
	Concentration	3905	4	14.31	<0.001
	Interaction	3747	4	13.73	<0.001
	Residuals	12280	180		
		<i>Sum of squared</i>	<i>DF</i>	<i>F-ratio</i>	<i>P-value</i>
Secondary diameter (D2)	Doped metal	2.07	1	24.06	< 0.001
	Concentration	6.11	4	17.70	< 0.001
	Interaction	1.66	4	4.18	0.001
	Residuals	15.54	180		

* For each parameter, the analysis compares the main effect of types of metal doped with TiO_2 , concentration levels of nanoparticles, and their interaction effect.

Compare to the control group, it appears that increasing the concentration level of doped TiO_2 NPs to 32 or 100 mg L^{-1} , has inflated the secondary lamellae diameter, D2, significantly. This is in contrary with our conclusion about length of primary gill length where increasing concentration levels resulted in shorter lengths. The broad conclusion of Figure 2 is that by increasing concentration levels one should expect shorter length of primary lamella but larger diameter of secondary lamellas. Again, differences are notable at 100 mg L^{-1} concentration of Cr and Ba doped TiO_2 NPs.

Another important question is to know whether the type of metals makes a significant difference in the gills parameters when doping with TiO_2 . Back to results, Table 1 suggests no significant effect on L1 ($F_{L1} [1, 180] = 0.56$; $p = 0.45$), significant effect on D1 ($F_{D1} [1, 180] = 0.56$; $p = 0.02$), and a highly significant effect on D2 ($F_{D2} [1, 180] = 0.56$; $p < 0.001$). Furthermore, type of metal affects the gill parameters in another way; it interacts with concentration levels and can result in drastic modification in lamella length or diameter depending on which concentration level is used ($F_{L1 \times M} [4, 180] = 4.48$; $p = 0.002$; $F_{D1 \times M} [4, 180] = 4.48$; $p < 0.001$; $F_{D2 \times M} [4, 180] = 4.48$; $p = 0.001$).

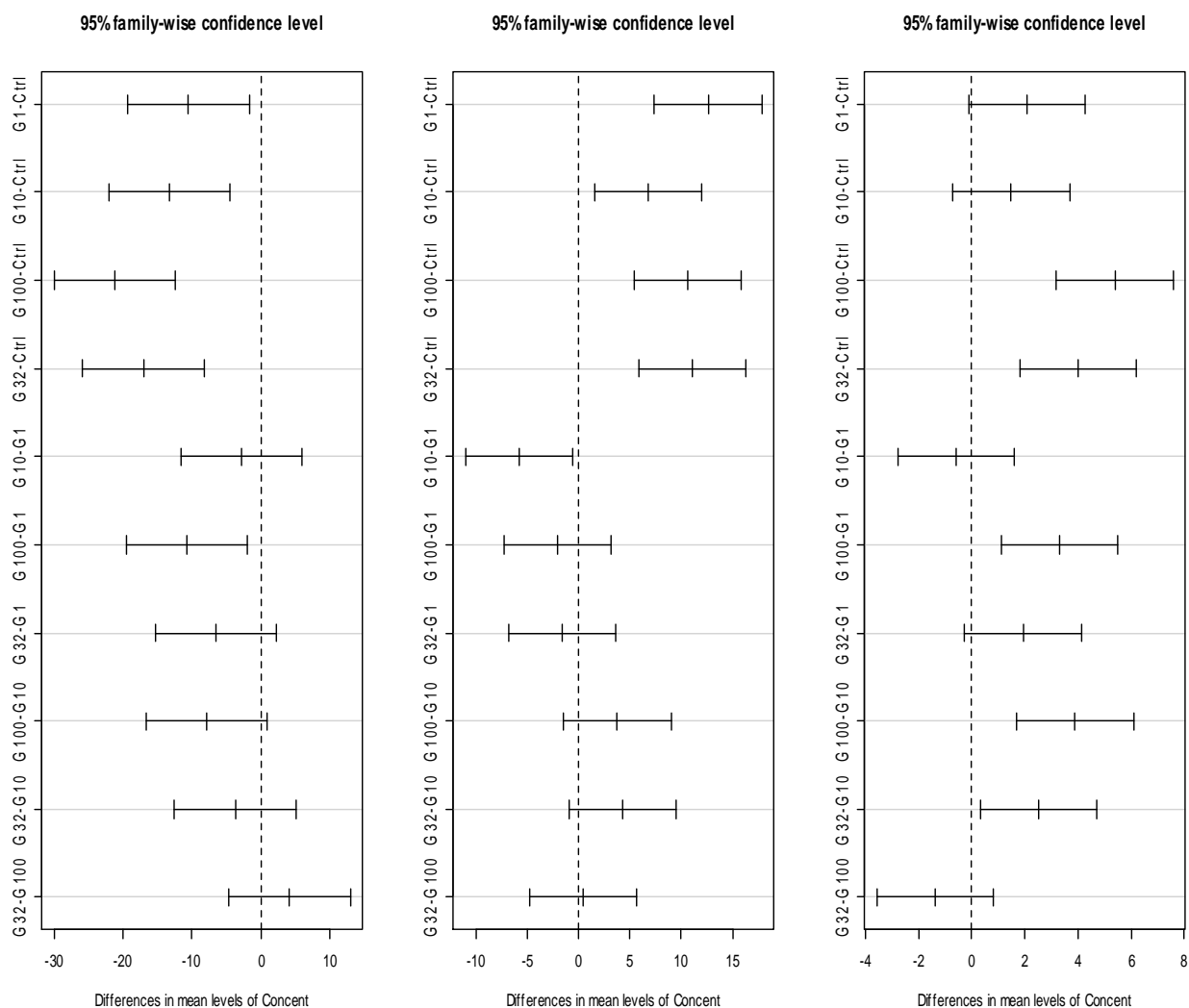


Figure 2. The 95% Tukey HSD pair-wise confidence intervals of differences in the mean levels of gill parameters (L1, D1, and D2) between different concentration levels. Left panel: primary diameter of gill lamellas, middle panel: secondary diameter of gill lamellas, and right panel: the length of secondary lamellas. In this plot, Ctrl represents control group, G1; 1 mg L⁻¹, G10; 10 mg L⁻¹, G32; 32 mg L⁻¹, and G100; 100 mg L⁻¹ concentration level.

The nature of interactions between type of metals and gills parameters is given by Figure 3. As it can be seen, regardless of which metal dopes with titanium oxide, at 0 mg L⁻¹ (control group) *D. rerio* have longer length (L1), but depending on doping metal, it begins to decrease in different manner as concentration level increases. For instance at 10 mg L⁻¹, reduction in primary length of lamella with Cr is much more intense than the length reduction with Ba (95% error bars do not overlap). The trend is inverse at 100 mg L⁻¹ when Ba results in much shorter L1. As we outlined earlier, the primary and secondary diameter of lamellae, D1 and D2, tend to increase with raising concentration levels, but the rate of increase cover with types of doped metal.

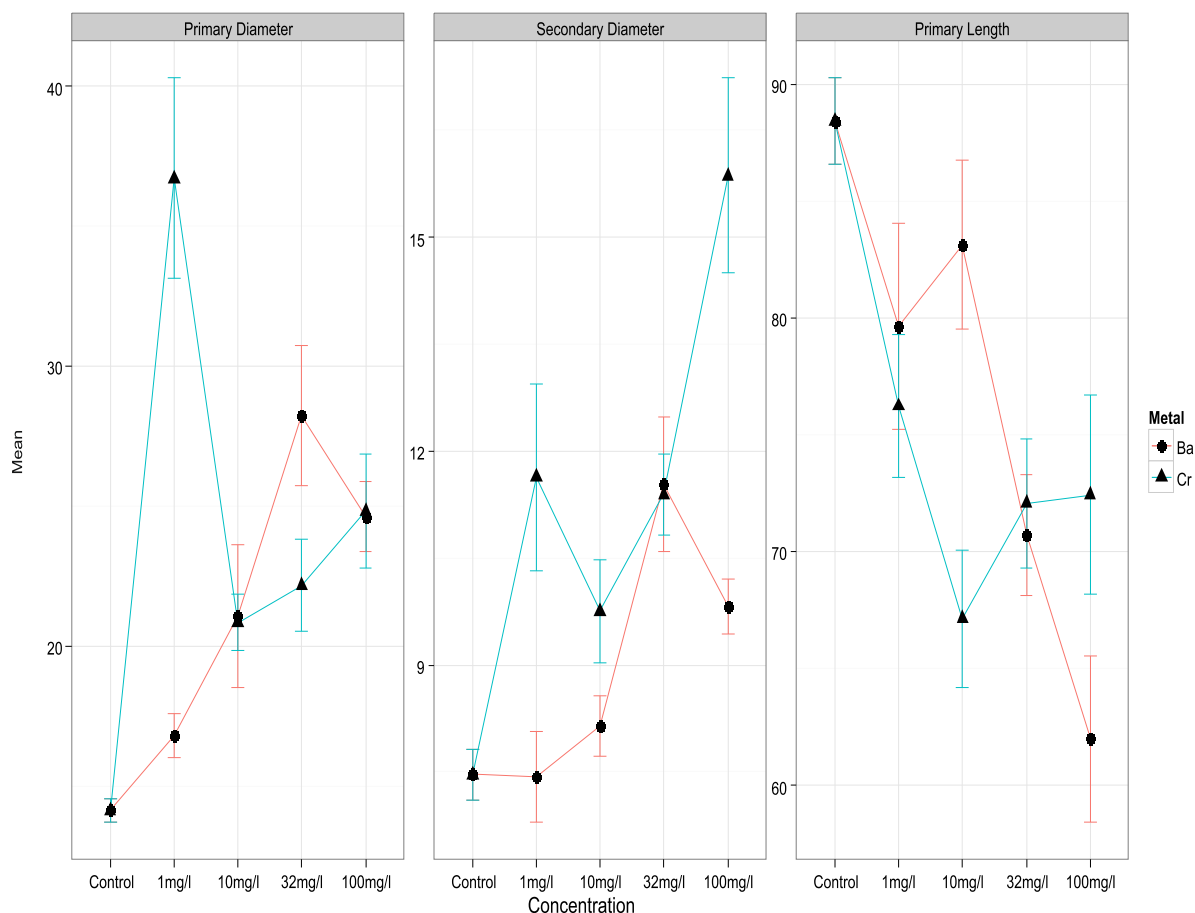


Figure 3. Interaction plots with 95% error bars of Cr/Ba-doped TiO₂ NPs and concentration levels for left panel: primary diameter of gill lamellas, middle panel: secondary diameter of gill lamellas, and right panel: the length of secondary lame.

Figure 4 shows gill morphology with highlighting for histopathological alterations under experimental groups exposed to Cr doped TiO₂ nanoparticles. Histopathological alterations resulted from Ba doped TiO₂ NPs at experimental groups are given by Figure 5. In control group, gill filaments and primary lamellae appeared to have normal histology (Figure 4 and 5, E). It turns out that four days exposure to Cr and Ba doped TiO₂ nanoparticles caused injuries in the gill. Most injuries include vacuoles, aneurism, dilated and clubbed tips, hyperplasia, oedema, curvature, fusion of lamellae, increase of mucous secretion, hypertrophy, and proliferation in the erythrocytes of cartilaginous core (Figure 4 & 5). However, at concentration level 1.0 mg L⁻¹ of NPs, minimum changes in primary and secondary lamellae were observed for both metals. By increasing the level of NPs concentration, the severity of damage increased, so that, sever injuries i.e. fusion and necrosis were observed at 100 mg L⁻¹. Compare to the control group, the thickening of secondary lamellae has irregular pattern (Figure 4 and 5). Aneurism and fusion of the boundary of primary and secondary lamellae increased with concentration levels. Gills in contact with 32 and 100 mg L⁻¹ concentrations, showed lamellar fusion in various areas of the secondary lamellae along with hyperplasia in chloride, pillar, pavement, and mucus secreting goblet cells.

In aquatic organisms such as fish, gills are vital organs for their multifunctional roles including respiratory organs and participate in many physiological activities, including respiratory, metabolites excretion, body fluid permeability balance and acid–base regulation balance; moreover, it used the first organs for contacting exogenous toxicants in aquatic environment (Nowrouzi et al 2012; Baramaki et al 2012; Majnoni et al 2013). Histopathological alterations in gill may lead to some functional impairments in fish, including respiration, osmoregulation, acid-base balance, and excretion of metabolite. Thus, gill histopathology appears to be a good biomarker for evaluation of

environmental stress (Pereira et al 2013; Hassaninezhad et al 2014; da Cruz et al 2015). In accordance with Nero et al (2006), we also found lamellar synechia. The mucus secretion increased from the epithelium of the secondary lamellae and this condition resulted in the fusion of secondary gill lamellae resulting in impaired respiration. Moreover, it has been demonstrated that the increased mucous secretion and hyperplasia of lamellae may make a barrier for NPs accumulate by the gills and would increase the diffusion distance for gas exchange (Scown et al 2010; Wang et al 2015b). In this study, exposure to Cr/Ba doped TiO_2 NPs caused lesion of lamellar fusion in gill of *D. rerio*. Lamellar fusion is defence mechanisms of fish gill that reduces the total respiratory area if it is in contact with the external environment. This alteration can cause a decrease in oxygen-uptake for total metabolic activities hence affecting the general health of fish (Pereira et al 2013; Subashkumar & Selvanayagam 2014).

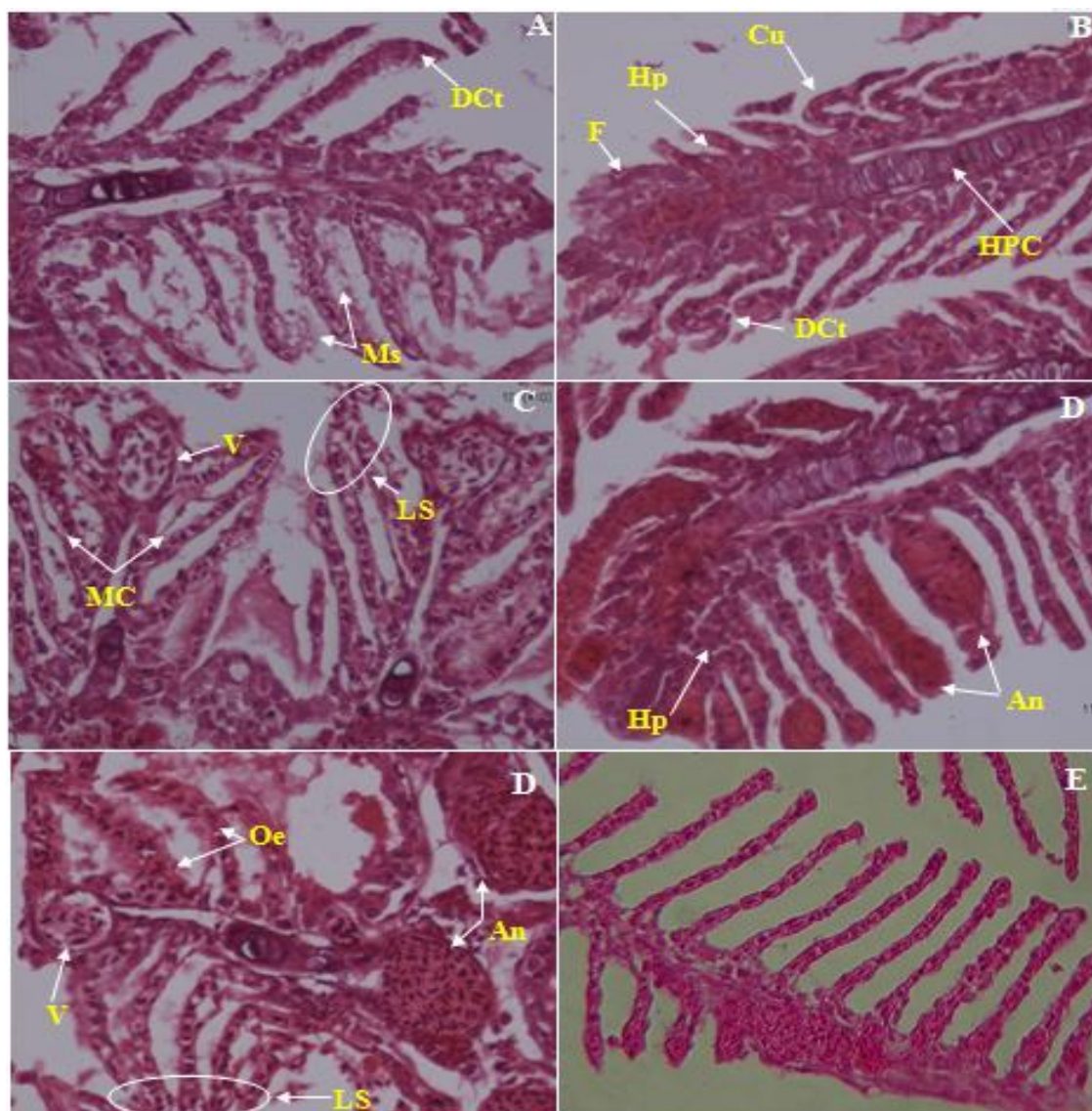


Figure 4. Gill morphology in *Danio rerio* exposed to Cr doped TiO_2 nanoparticles for 4 days. The panels include (A) 1 mg L^{-1} , (B) 10 mg L^{-1} , (C) 32 mg L^{-1} , (D) 100 mg/L , and (E) control group. The gills of control fish indicated normal histology, whilst all treatments showed injuries that include vacuoles (Va), aneurism (An), dilated and clubbed tips (DCt), hyperplasia (Hp), oedema (Oe), curvature (Cu), fusion of lamellae (F), increase of mucous secretion (Ms), dilated marginal channel (MC), lamellar synechia (LS), hypertrophy and proliferation in the erythrocytes of cartilaginous core (HPC) (original).

In this study, hyperplasia, fusion of lamellae and formation of aneurism were seen in gill. The lesions observed in lamellar aneurysm can be due to the disturbance of blood flow in

the blood channels. Aneurism is blood-filled and swelling blood vessel. This condition in the gill tissue may lead to disturbances in blood flow in the gill, increasing the risk of rupture, and bleeding or death (Flores-Lopes & Thomaz 2011; Rajkumar et al 2015). These types of lesion occur as a tissue reaction to diluted pollutants in water in order to increase the distance between the blood capillary and lamellae surface to reduce pollutant uptake (Liebel et al 2013). Rajkumar et al (2015) reported similar findings about aneurism lesions in the gill of fish after exposure to silver NPs. Al-bairuty (2013) indicated that presentation of copper NPs in water can increase the incidence of edema in the secondary lamellae, lamellar fusion, clubbed tips, hyperplasia, aneurisms, and necrosis in the secondary lamellae of the gills filaments in rainbow trout.

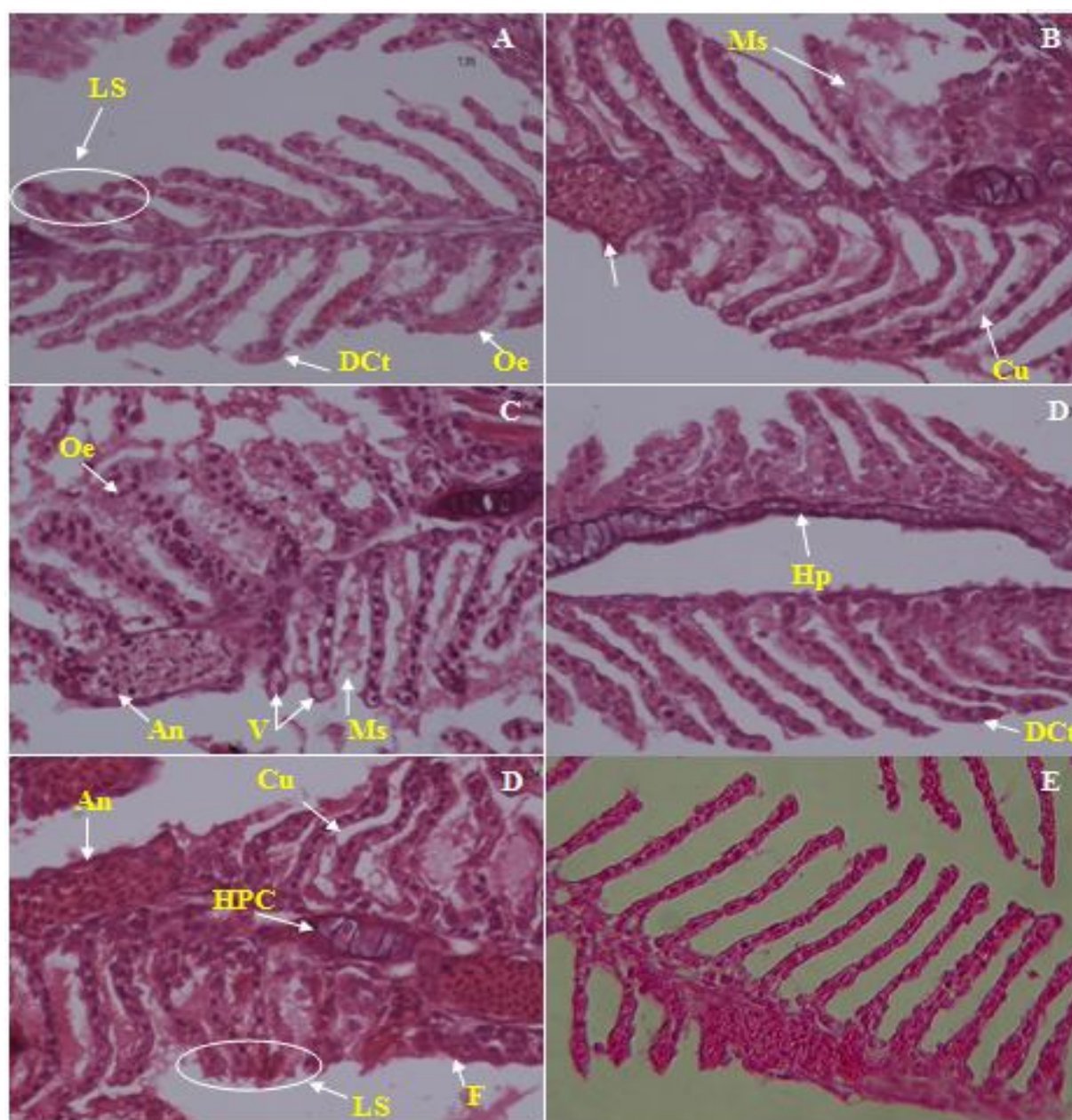


Figure 5. Gill morphology in *Danio rerio* exposed to Ba doped TiO_2 nanoparticles for 4 days. The panels include (A) 1 mg L^{-1} , (B) 10 mg L^{-1} , (C) 32 mg L^{-1} , (D) 100 mg L^{-1} , and (E) control group. The gills of control fish indicated normal histology, whilst all treatments showed injuries that include vacuoles (Va), aneurism (An), dilated and clubbed tips (DCt), hyperplasia (Hp), oedema (Oe), curvature (Cu), fusion of lamellae (F), lamellar synechia (LS), increase of mucous secretion (Ms), hypertrophy and proliferation in the erythrocytes of cartilaginous core (HPC) (original).

Histopathological anomalies in the gill have been seen in other species. Federici et al (2007) and Linhua et al (2009) found that exposure to TiO₂ NPs enhances the incidence of edema, and thickening of gill lamellae and filaments of rainbow trout and carp. Moreover, Griffitt et al. (2007) found filament and lamellar fusion in *D. rerio* gill after treating with Cu-NPs suspensions; edema of primary and secondary gill filaments of *D. rerio* was also identified. In another comparative study, Griffitt et al (2009) showed that compare to control group, gill filaments were threefold thicker in fish at Cu-NPs exposed group, but no significant changes at gill filaments in both TiO₂ NPs and Ag NPs groups. A reaction to intake toxicants, an adaptation response to prevent the entry of the pollutants thorough the gill surface, and capillary permeability can be account for these pathological changes (Olurin et al 2006). In our study, we found injuries in gill lamella and filaments. The extent of damages on gill depended on concentration level of nanoparticles; more severe injuries were observed at 100 mg L⁻¹ treatment group (Table 1). Duration exposure can be another factor causing damages in gill. However, in this study, we did not assess this effect. Generally speaking, gill pathological data suggest that degenerative changes were the most prevalent and sensitive changes observed following exposure of *D. rerio* to metal doped TiO₂ NPs. The toxicity caused by Cr-doped TiO₂ NPs on the gills of *D. rerio* has been more than Ba-doped TiO₂ NPs. Hence the use of this compound in various sectors will need to manage properly and need to be included in the assessment of toxicological impacts in the aquatic environment.

Conclusions. Our findings show that the extent of tissue damages increased by concentration levels of NPs; however, the severity of histopathological anomalies in gill of *D. rerio* caused by Cr-doped TiO₂ NPs was more notable than that of observed by Ba-doped TiO₂ NPs.

Acknowledgement. This work was supported by the Kurdistan University of Medical Sciences under Grant [number 14/15074]. The contribution of the Student Committee Center of Kurdistan University of Medical Sciences is also sincerely appreciated.

References

- Ahmed M. K., Kundu G. K., Al-Mamun M. H., Sarkar S. K., Akter M. S., Khan M. S., 2013 Chromium (VI) induced acute toxicity and genotoxicity in freshwater stinging catfish, *Heteropneustes fossilis*. *Ecotoxicology and Environmental Safety* 92:64–70.
- Al-bairuty G. A. A. L., 2013 Histopathological effects of metal and metallic nanoparticules on the body systems of rainbow trout (*Oncorhynchus mykiss*). PhD thesis, School of Biomedical and Biological Sciences, University of Plymouth, 419 pp.
- Ates M., Demir V., Adiguzel R., Arslan Z., 2013 Bioaccumulation, subacute toxicity, and tissue distribution of engineered titanium dioxide nanoparticles in goldfish (*Carassius auratus*). *Journal of Nanomaterials*, Article ID 460518, <http://dx.doi.org/10.1155/2013/460518>
- Begum G., Venkateswara R. J., Srikanth K., 2006 Oxidative stress and changes in locomotor behavior and gill morphology of *Gambusia affinis* exposed to chromium. *Toxicology and Environmental Chemistry* 88:355–365.
- Baramaki R., Ebrahimpour M., Mansouri B., Rezaei M. R., Babaei H., 2012 Contamination of metals in tissues of *Ctenopharyngodon idella* and *Perca fluviatilis*, from Anzali Wetland, Iran. *Bulletin of Environmental Contamination and Toxicology* 89:831-835.
- Chevreuil M., Carru A. M., Chesterikoff A., Boët P., Tales E., Allardi J., 1995 Contamination of fish from different areas of the river Seine (France) by organic (PCB and pesticides) and metallic (Cd, Cr, Cu, Fe, Mn, Pb, and Zn) micro pollutants. *The Sciences of the Total Environment* 162(1):31–42.
- da Cruz A. L., Prado T. M., da Silva Maciel L. A., Couto R. D., 2015 Environmental effects on the gills and blood of *Oreochromis niloticus* exposed to rivers of Bahia, Brazil. *Ecotoxicology and Environmental Safety* 111:23–31.

- Fan W. H., Cui M. M., Shi Z. W., Tan C., Yang X. P., 2012 Enhanced oxidative stress and physiological damage in *Daphnia magna* by copper in the presence of nano-TiO₂. Journal of Nanomaterials DOI:10.1155/2012/398720.
- Federici G., Shaw B. J., Handy R. D., 2007 Toxicity of titanium dioxide nanoparticles to rainbow trout (*Oncorhynchus mykiss*): gill injury, oxidative stress, and other physiological effects. Aquatic Toxicology 84:415–430.
- Fernando V. K., Perera I. C., Dangalle C. D., Premawansa S., Wijesinghe M., 2015 Histological alterations in the body wall of the tropical earthworm *Eudrilus eugeniae* exposed to hexavalent chromium. Bulletin of Environmental Contamination and Toxicology DOI: 10.1007/s00128-015-1480-1.
- Flores-Lopes F., Thomaz A. T., 2011 Histopathological alterations observed in fish gills as a tool in environmental monitoring. Brazilian Journal of Biology 71:179-188.
- Griffitt R. J., Weil R., Hyndman K. A., Denslow N. D., Powers K., Taylor D., Barber D. S., 2007 Exposure to copper nanoparticles causes gill injury and acute lethality in zebrafish (*Danio rerio*). Environmental Sciences Technology 41:8178–8186.
- Griffitt R. J., Hyndman K., Denslow N. D., Barber D. S., 2009 Comparison of molecular and histological changes in zebrafish gills exposed to metallic nanoparticles. Toxicology Sciences 107:404-415.
- Hassaninezhad L., Safahieh A., Salamat N., Savari A., Erfani Majd N., 2014 Assessment of gill pathological responses in the tropical fish yellowfin seabream of Persian Gulf under mercury exposure. Toxicology Report 1:621–628.
- Hao L., Wang Z., Xing B., 2009 Effect of sub-acute exposure to TiO₂ nanoparticles on oxidative stress and histopathological changes in juvenile carp (*Cyprinus carpio*). Journal of Environmental Sciences 21:1459–1466.
- Jacobs I. A., Taddeo J., Kelly K., Valenziano C., 2002 Poisoning as a result of barium styphnate explosion. American Journal of Industrial Medicine 41:285–288.
- Jaishankar M., Tseten T., Anbalagan N., Mathew B. B., Beeregowda K. N., 2014 Toxicity, mechanism and health effects of some heavy metals. Interdisciplinary Toxicology 7(2):60–72.
- Jiss J., Prachi S., Rajendran N., 2014 Nanotoxicity of materials on marine and aquatic organisms. International Journal of Pharmacology and Sciences Review Research 27(2):117-124.
- Kumar P., Kumar R., Nagpure N. S., Nautiyal P., Kushwaha B., Dabas A., 2013 Genotoxicity and antioxidant enzyme activity induced by hexavalent chromium in *Cyprinus carpio* after in vivo exposure. Drug Chemistry and Toxicology 5:1–10.
- Kuperman R. G., Checkai R. T., Simini M., Phillips C. T., Speicher J. A., Barclift D. J., 2006 Toxicity benchmarks for antimony, barium, and beryllium determined using reproduction endpoints for *Folsomia candida*, *Eisenia fetida*, and *Enchytraeus crypticus*. Environmental Toxicology and Chemistry 25:754–762.
- Linhua H., Zhenyu W., Baoshan X., 2009 Effect of sub-acute exposure to TiO₂ nanoparticles on oxidative stress and histopathological changes in Juvenile Carp (*Cyprinus carpio*). Journal of Environmental Sciences 21:1459-1466.
- Liebel S., Tomotake M. E. M., Oliveira ribeiro C. A., 2013 Fish histopathology as biomarker to evaluate water quality. Ecotoxicology and Environmental Contamination 8:09-15.
- Lhomme L., Brosillon S., Wolbert D., Dussaud J., 2005 Photocatalytic degradation of a phenylurea, chlortoluron, in water using an industrial titanium dioxide coated media. Applied Catalyst B: Environment 61:227-235.
- Llugany M., Poschenrieder C., Barcelo J., 2000 Assessment of barium toxicity in bush beans. Archives of Environmental Contamination and Toxicology 39:440–444.
- Majnoni F., Mansouri B., Rezaei M. R., Hamidian A. H., 2013 Contaminations of metals in tissues of common carp, *Cyprinus carpio* and silver carp, *Hypophthalmichthys molitrix* from Zarivar wetland, western Iran. Archives of Polish Fisheries 21:11-18.
- Mansouri B., Maleki A., Johari S. A., Reshahmanish N., 2015 Effects of cobalt oxide nanoparticles and cobalt ions on gill histopathology of zebra fish (*Danio rerio*). AACL Bioflux 8(3):438-444.

- Maynard A., Michelson E., 2006 The nanotechnology consumer products inventory. Woodrow Wilson International Center for Scholars, Washington, DC, accessed March 23.
- Mishra A. K., Mohanty B., 2008 Acute toxicity impacts of hexavalent chromium on behavior and histopathology of gill, kidney and liver of the freshwater fish, *Channa punctatus* (Bloch). Environmental Toxicology and Pharmacology 26:136–141.
- Mishra A. K., Mohanty B., 2009 Chronic exposure to sublethal hexavalent chromium affects organ histopathology and serum cortisol profile of a teleost, *Channa punctatus* (Bloch). Sciences of the Total Environment 407(18):982–989.
- Muneer M., Singh H. K., Bahnemann D., 2002 Photocatalysed degradation of two selected priority organic pollutants, benzidine and 1,2-diphenyl hydrazine in aqueous suspensions of titanium dioxide. Chemosphere 49:193-203.
- Nath K., Kumar N., Srivastav A. K., 1997 Chromium induced histological alterations in the gills of a freshwater teleost, *Colisa fasciatus*. Fish Biology Journal of Medaka 9:37–40.
- Nero V., Farwell A., Lister A., Kraak G., Lee L. E. J., Meer T., MacKinnon M. D., Dixon D. G., 2006 Gill and Liver Histopathological Changes in Yellow Perch (*Perca flavescens*) and goldfish (*Cassius auratus*) Exposed to Oil Sands Process-Affected Water. Ecotoxicology and Environmental Safety 63:365–377.
- Nowrouzi M., Mansouri B., Hamidian A. H., Zarei I., Mansouri A., 2012 Metal contents in tissues of two fish species from Qeshm Island, Iran. Bulletin of Environmental Contamination and Toxicology 89:1004-1008.
- Olurin K., Olojo E., Mbaka G., Akindele A., 2006 Histopathological responses of the gill and liver tissues of *Clarias gariepinus* fingerlings to the herbicide, glyphosate. African Journal of Biotechnology 5:2480-2487.
- Parvathi K., Sivakumar P., Sarasu C., 2011 Effects of chromium on histological alterations of gill, liver, and kidney of freshwater Teleost, *Cyprinus carpio* (L.). Journal of Fisheries International 6:1-5.
- Pereira S., Pinto L. A., Cortes R., Fontanhas-Fernandes A., Coimbra A. M., Monteiro S. M., 2013 Gill histopathological and oxidative stress evaluation in native fish captured in Portuguese northwestern rivers. Ecotoxicology and Environmental Safety 90:157-166.
- Purdey M., 2004 Chronic barium intoxication disrupts sulphated proteoglycan synthesis: a hypothesis for the origins of multiple sclerosis. Medicine Hypotheses 62(5):746-754.
- Pais I., Jones J. B., 1998 The handbook of trace elements. St Lucie Press, Boca Raton, FL.
- Rajkumar K. S., Kanipandian N., Thirumurugan R., 2015 Toxicity assessment on haematology, biochemical and histopathological alterations of silver nanoparticles-exposed freshwater fish *Labeo rohita*. Applied Nanosciences doi: 10.1007/s13204-015-0417-7.
- Rajaei G., Mansouri B., Jahantigh H., Hamidian A. H., 2012 Heavy metal concentrations in the water of the Chah nimeh reservoirs from Zabol, Iran. Bulletin of Environmental Contamination and Toxicology 89:495–500.
- Rana S., Kalaichelvan P. T., 2013 Ecotoxicity of nanoparticles. Toxicology dx.doi.org/10.1155/2013/574648
- Scown T. M., Santos E. M., Johnston B. D., Gaiser B., Baalousha M., Mitov S., Lead J. R., 2010 Effects of aqueous exposure to silver nanoparticles of different sizes in rainbow trout. Toxicology Sciences 115:521–534.
- Subashkumar S., Selvanayagam M., 2014 First report on: Acute toxicity and gill histopathology of fresh water fish *Cyprinus carpio* exposed to zinc oxide (ZnO) nanoparticles. International Journal of Sciences Research Public 3:1-4.
- Tian B., Li C., Zhang J., 2012 One-step preparation, characterization and visible-light photocatalytic activity of Cr-doped TiO₂ with anatase and rutile bicrystalline phases. Chemistry Engineering Journal 191:402–409.
- Wang D. Y., Wang Y., 2008 Phenotypic and behavioral defects caused by barium exposure in nematode *Caenorhabditis elegans*. Archives of Environmental Contamination and Toxicology 54:447–453.

- Wang W., Ye Y., Feng J., Chi M., Guo J., Yin Y., 2015a Enhanced photoreversible color switching of redox dyes catalyzed by barium-doped TiO₂ nanocrystals. *Angewandte Chemistry* 127:1337-1342.
- Wang T., Long X., Liu Z., Cheng Y., Yan S., 2015b A Comparison effect of copper nanoparticles versus copper sulphate on Juvenile *Epinephelus coioides*: growth parameters, digestive enzymes, body composition, and histology as biomarkers. *International Journal of Genome* 2015:1-10.
- Wang D., Hu J., Irons D. R., Wang J., 2011 Synergistic toxic effect of nano-TiO₂ and As (V) on *Ceriodaphnia dubia*. *The Sciences of the Total Environment* 409:1351–1356.
- Wepener V., Van Vuren J. H. J., Du Preez H. H., 1992 The effect of hexavalent chromium at different pH values on the hematology of *Tilapia sparrmanii* (Cichlidae). *Comparative Biochemistry and Physiology* 101(2): 375–81.
- Yeo M. K., Park H. G., 2012 Gene expression in zebrafish embryos following exposure to Cu-doped TiO₂ and pure TiO₂ nanometer-sized photocatalysts. *Molecular Cells Toxicology* 8: 127-137.
- Yeo M. K., Kang M., 2010 The effect of nano-scale Zn-doped TiO₂ and pure TiO₂ particles on *Hydra magnipapillata*. *Molecular Cells Toxicology* 6: 9-17.
- Zhang D., 2011 Chemical synthesis of Ni/TiO₂ nanophotocatalyst for UV/visible light assisted degradation of organic dye in aqueous solution. *Journal of Sol-Gel Sciences Technology* 58:312–318.
- *** BCC Research, 2010 Nanotechnology - Nanocomposites, Nanoparticles, Nanoclays, and 634 Nanotubes, BCC Research, NAN021D. <http://www.bccresearch.com/market-research/nanotechnology/nano-composites-particles-clays-tubes-nan021d.html>
- *** European Commission, 2015 http://ec.europa.eu/enterprise/sectors/chemicals/reach/nanomaterials/index_en.htm, 24.07.2015
- *** Woodrow Wilson Database., 2014 Nanotechnology consumer product inventory. <http://www.nanotechproject.org/cpi/about/analysis/>

Received: 20 July 2016. Accepted: 28 August 2016. Published online: 30 August 2016.

Authors:

Raouf Rahmani, Kurdistan University of Medical Sciences, Environmental Health Research Center, Iran, Sanandaj 66177-13446, Pasdaran Street, e-mail: rr78muk@yahoo.com

Borhan Mansouri, Kurdistan University of Medical Sciences, Student Research Committee, Iran, Sanandaj 66177-13446, Pasdaran Street, e-mail: borhanmansouri@yahoo.com

Nammam Ali Azadi, Iran University of Medical Sciences, School of Public Health, Biostatistics Department, Iran, Tehran, e-mail: n.azadi@hotmail.com

Behroz Davari, Hamadan University of Medical Sciences, School of Medicine, Department of Medical Entomology, Iran, Hamadan, e-mail: davaribehroz@yahoo.com

Seyed Ali Johari, University of Kurdistan, Faculty of Natural Resources, Department of Fisheries, University of Kurdistan, Iran, Kurdistan, Sanandaj, Postal Code: 66177-15175, P.O. Box 416, e-mail: a.johari@uok.ac.ir

Afshin Maleki, Kurdistan University of Medical Sciences, Environmental Health Research Center, Iran, Sanandaj 66177-13446, Pasdaran Street, e-mail: maleki43@yahoo.com

Mohammad Amin Pordel, Kurdistan University of Medical Sciences, Environmental Health Research Center, Iran, Sanandaj 66177-13446, Pasdaran Street, e-mail: mapordel1@gmail.com

This is an open-access article distributed under the terms of the Creative Commons Attribution License, which permits unrestricted use, distribution and reproduction in any medium, provided the original author and source are credited.

How to cite this article:

Rahmani R., Mansouri B., Azadi N. A., Davari B., Johari S. A., Maleki A., Pordel M. A., 2016 Histopathological alterations in the gill of zebrafish (*Danio rerio*) exposed to Cr and Ba doped TiO₂ nanoparticles. *AACL Bioflux* 9(4):889-900.